

CASE REPORT

ANESTHETIC MANAGEMENT OF A KNOWN CASE OF EBSTEIN'S ANOMALY POSTED FOR HEMITHYROIDECTOMY: A CASE REPORT

Snehalatha Bhashyam¹, P. Krishna Prasad², B. Sowbhagya Lakshmi³, K. V.P. Bramhaji Rao⁴

HOW TO CITE THIS ARTICLE:

Snehalatha Bhashyam, P. Krishna Prasad, B. Sowbhagya Lakshmi, K. V.P. Bramhaji Rao. "Anesthetic Management of a Known Case of Ebstein's Anomaly Posted for Hemithyroidectomy: A Case Report". Journal of Evolution of Medical and Dental Sciences 2014; Vol. 3, Issue 50, October 06; Page: 11860-11865, DOI: 10.14260/jemds/2014/3562

ABSTRACT: BACKGROUND: The rare congenital heart defect of Ebstein's anomaly is characterized by downward displacement and elongation of the tricuspid valve with poorly contractile right ventricle, an enlarged right atrium along with tricuspid regurgitation. It is frequently associated with intracardiac shunting, pulmonary hypertension, cardiac dysrhythmias, cyanosis and particularly associated with Wolf-Parkinson-White syndrome (up to 20 % of patients). Supra ventricular and ventricular arrhythmias are common. Congestive heart failure and sudden collapse are the most common causes of death. The complications following thyroid surgery are rare due to better preoperative preparations and proper surgical techniques, however, complications like hematoma formation and recurrent laryngeal nerve injury are known to cause airway obstruction and can be fatal. Here we report the successful management of a 45 year old euthyroid patient, a known case of Ebstein's anomaly who underwent Hemithyroidectomy under General anaesthesia (G.A) Perioperative management was uncomplicated with good hemodynamic stability and patient was discharged without any untoward problem.

KEYWORDS: Ebstein's anomaly, Hemithyroidectomy, General anaesthesia, hemodynamic stability.

INTRODUCTION: Wilhelm Ebstein first described the clinical and anatomical features of an anomaly of the tricuspid valve in 1866.¹ which occurs in 1 percent of congenital heart defects (1 in 110,000 of the general population). It is characterized by dysplastic abnormalities of both basal and free attachments of the tricuspid valve leaflets, with downward displacement and elongation of the septal and anterior cusp,² with resulting tricuspid regurgitation.³ It is frequently associated with intracardiac shunting, pulmonary hypertension, cardiac dysrhythmias, cyanosis⁴ and particularly associated with Wolf-Parkinson-White syndrome (up to 20 % of patients).⁵ Congestive heart failure and sudden collapse are the most common causes of death. Here we present a case of Thyroid Nodule left side neck of a female aged 45 years who is euthyroid with known Ebstein's anomaly, who had undergone Hemithyroidectomy, under general anaesthesia.

CASE REPORT: A 45 year old female weighing 50 kgs presented with thyroid swelling of 1 year duration. The swelling was confined to neck and there was no retrosternal extension. There were no symptoms or signs suggestive of hypo or hyperthyroidism and pressure effects on trachea. She is a known case of Ebstein's anomaly. She complained of occasional palpitations, and dyspnoea on moderate exertion. She had history of recurrent chest infections. There was no history of cyanotic spells and syncopal attacks. There was no significant family history and she had no addictions. She is on treatment with Tab: Digoxin 0.25 mg per day for 5 days a week since 10 years for her Cardiac ailment.

CASE REPORT

On examination, she was found to be an average-build lady with regular pulse, she was normotensive with no pedal edema, no lymphadenopathy, Jugular venous pressure was not raised there is no pallor or cyanosis. There is swelling in front of neck on left side. Mouth opening was adequate with Mallampatti grade-I. Neck movements are normal. TM joint and thyromental distance are normal. Examination of cardiovascular system revealed the presence of a loud pansystolic murmur, best heard in the tricuspid area. Liver was not palpable and there were no other signs of heart failure at the time of presentation.

Investigations showed haemoglobin of 11.1 gm%, normal blood counts, normal liver/renal functions, normal blood sugar, normal serum Electrolytes and Calcium. Her ABG report was normal. The ECG showed normal sinus rhythm with right axis deviation but no arrhythmias. Chest X-ray showed enlarged right atrium with cardiomegaly, while 2D echocardiogram showed the presence of moderately enlarged right atrium and ventricle, tricuspid regurgitation with downwardly displaced tricuspid valves, confirming diagnosis of Ebstein's anomaly. There was no atrial septal defect or pulmonary hypertension.

There is depressed right ventricular systolic function but the left ventricular function was normal. Thyroid function tests were within normal limits. T₃- 1.75 ng/ml; T₄- 11.78 µg/dl; TSH- 0.99 µIU/ml. Preoperative indirect laryngoscopy showed normal vocal cord movements. The x-ray of the neck did not reveal any deviation or compression of the trachea. Preoperative fine needle aspiration cytology was suggestive of a benign cystic lesion of thyroid. The patient was referred to the physician for complete evaluation and management.

Written and informed consent was taken prior to surgery, and the risks involved with surgery and anaesthetic management were explained to the patient and attendants. General anesthesia was planned for Hemithyroidectomy. She was pre medicated with diazepam 5 mg on the night before surgery. The prophylaxis against infective endocarditis was adopted as per protocol. In the operating room, Urinary Catheterization was done under strict aseptic conditions. After securing intravenous access with an 18 G cannula, Inj: midazolam 1mg IV and Inj: fentanyl 2 µg/kg IV was administered. Routine monitoring was done with electrocardiogram, non-invasive blood pressure (NIBP), pulse oximetry, EtCO₂ and nasopharyngeal temperature probe, BIS monitoring was also instituted. ECG was continuously monitored, defibrillator and all the emergency Drugs kept ready and Central venous catheter was not inserted because of the increased risk of tachyarrhythmias.

Pre oxygenation was done for 5 minutes. Anesthesia was induced with Etomidate 0.3 mg/kg IV given titrated to loss of eyelash reflex along with isoflurane 0.8 % and Oxygen and nitrous oxide 50:50 as there is no PAH. Vecuronium intubation was done with a loading dose of 0.1mg/kg as the airway is normal with Mallampatti Grade -I, ventilated for 3 minutes and after relaxation was achieved the patient was intubated with a 7.0 mm ID cuffed endotracheal tube. After induction of anesthesia, a 20 G arterial cannula was placed in the left radial artery under strict aseptic conditions for IBP Monitoring.

Anesthesia was maintained with Vecuronium incremental doses, oxygen, nitrous oxide and isoflurane 0.8 to 1% on a circle system with controlled ventilation. After 1 hour of surgery Inj: fentanyl 20 µg IV was administered to maintain stable HR. Our patient was hemodynamically stable throughout the operation, with mean arterial pressure between 70 and 90 mmHg and HR between 75 and 90/min. The patient was ventilated using Volume Control Ventilation on anaesthesia work station with the following settings: tidal volume-500 mL; rate-14/min; I:E ratio-1:2; paw limit-35

CASE REPORT

mmHg; no positive end-expiratory pressure was used. The EtCo₂ remained between 28 and 32 mmHg and SpO₂ from 99 to 100%, BIS maintained around 40-50.

The total duration of surgery was around 120 minutes (2hr). Upon completion of surgery, superficial cervical plexus block (regional block) with 10 CC of 0.2% Ropivacaine was administered bilaterally for postoperative analgesia as a part of multimodal approach and reversal of neuromuscular blockade was achieved with neostigmine 2.5 mg and glycopyrrolate 0.4 mg. The recovery from anesthesia and extubation were uneventful with complete hemodynamic stability and the Patient was shifted to ICU for observation for 24 hours. A total of 1 L of crystalloid (Ringer's lactate) was used in the intraoperative period. Restricted fluid strategy was followed in the postoperative period also.

DISCUSSION: Ebstein's anomaly is a very rare congenital heart disease. There are few cells in Ebstein's right ventricle than are normally found, which contribute to ventricular dilatation in addition to tricuspid regurgitation.⁶ The linkage between thyroid disease and heart disease is established. Undiagnosed, untreated or undertreated hypothyroidism a condition of insufficient thyroid hormone can increase cholesterol levels and increases the risk of heart disease in adults. Hyperthyroidism a condition of an excess of thyroid hormone can also increase the risk of heart attacks, due to increased blood pressure, rapid heartbeat, and in some cases, palpitations and atrial fibrillation. As our patient is in Euthyroid state, anaesthetic management included prioritization in prevention and avoidance of Hemodynamic fluctuations in view of Cardiac ailment.

The American Heart Association has published updated guidelines for the prevention of infective endocarditis.⁷ Antibiotic prophylaxis for infective endocarditis was being administered for our patient as per protocol. Patients with Ebstein's anomaly already have a high propensity for tachy arrhythmias and paradoxical embolism, for which we avoided the insertion of central venous catheter.⁸ Basic principles of management of Ebstein's anomaly cases are;⁹ to maintain prelaod and after load and maintain sinus rhythm. Avoidance of tachycardia as this leads to impaired right ventricular filling.¹⁰

Atropine and ketamine precipitate tachycardia, therefore are avoided. Some evidence suggests that Etomidate may provide hemodynamic stability in the setting of CHD.¹¹ So Etomidate was being used as Induction Agent to attain hemodynamic stability. Fentanyl also provides adequate hemodynamic stability. Vecuronium and rocuronium are cardio stable muscle relaxants preferred over pancuronium and atracurium¹². These patients are prone to cardiac arrhythmias. Hence E.C.G was continuously monitored and a defibrillator was kept ready. Factors which are known to precipitate arrhythmias, e.g. light plane of anesthesia or a fluid or acid base disturbance were avoided.¹³ IV Fluids were restricted and given with meticulous titration because of the risk of right ventricular failure.

CONCLUSION: We conclude that the successful outcome of a patient with Ebstein's anomaly undergoing Hemithyroidectomy under General anaesthesia (G.A) depends on thorough understanding of pathophysiology of the cardiovascular disease, maintaining good hemodynamic stability and avoidance of Perioperative complications.

CASE REPORT

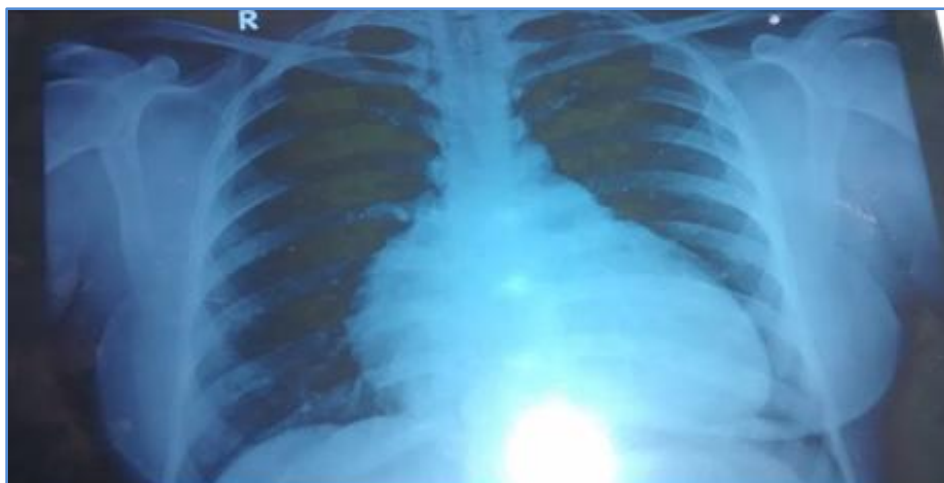ACKNOWLEDGMENT: Sri. Dr. Hari Prasad was the chief surgeon and provided the medical documents for the reported case.

We are grateful to our patient, who agreed to the reporting of this case report and provided all information needed.

REFERENCES:

1. Mann RJ, Lie JT. The life story of Wilhelm Ebstein (1836- 1912) and his almost overlooked description of a congenital heart disease. *Mayo Clin. Proc* 1979; 54: 197-203.
2. Donnelly JE, Brown JM, Radford DJ. Pregnancy outcome and Ebstein's anomaly. *Br Heart J* 1991; 66: 368 -71.
3. Dearani JA, Danielson GK. Surgical management of Ebstein's anomaly in the adult. *Semin Thorac Cardiovasc Surg* 2005; 17: 148-54.
4. Misa VS, Pan PH. Evidence based case report for analgesic and anaesthetic management of parturient with Ebstein's anomaly and Wolff-Parkinson- White syndrome. *Int J Obstet Anesth* 2007; 16: 77-81.
5. Groves ER, Groves JB. Epidural analgesia for labour in a patient with Ebstein's anomaly. *Can J Anaesth* 1995; 42: 77 - 9.
6. Loomba RS, Chandrasekar S, Sanan P, Shah PH, Arora RR. Association of atrial tachyarrhythmias with atrial septal defect, Ebstein's anomaly and Fontan patients. *Expert Rev Cardiovasc Ther.* 2011; 9 (7): 887-93.
7. Wilson W, Taubert KA, Gewitz M, Lockhart PB, Baddour LM, Levison M, et al. Prevention of infective endocarditis: Guidelines from the American Heart Association: A guideline from the American Heart Association Rheumatic Fever, Endocarditis, and Kawasaki Disease Committee, Council on Cardiovascular Disease in the Young, and the Council on Clinical Cardiology, Council on Cardiovascular Surgery and Anesthesia, and the Quality of Care and Outcomes Research Interdisciplinary Working Group. *Circulation* 2007; 116: 1736-54.
8. Horishita T, Minami K, Koga K, Ogata J, Sata T. Anesthetic management using echocardiography for surgery of lower extremity in a patient with Ebstein's malformation. *Anesth Analg* 2005; 101: 606-15.
9. Groves ER. Epidural analgesia for labour in a patient with Ebstein's anomaly. *Can J Anaesth* 1995; 42 (1): 77-79.
10. Dr Rathna, Dr Tejesh C.A, Dr Manjunath A.C, Dr Mathews K. Thomas. Anesthesia for incidental surgery in a patient with Ebstein's anomaly. *SAARC J. Anesth* 2008; 1 (1): 85-87.
11. Andropoulos DB, Stayer SA, Skjonsby BS, East DL, McKenzie ED, Fraser CD. Anesthetic and perioperative outcome of teenagers and adults with congenital heart disease. *J Cardiothorac Vasc Anesth* 2002; 2002: 731-6.
12. Hines RL, Marschall KE. Abnormalities of Cardiac Conduction and Cardiac Rhythm. In: Stoelting RK, Dierdorf SF, editors. *Anesthesia and co-existing disease*. 5th ed. Philadelphia: Churchill-Livingstone; 2008. p. 72-3.
13. Macflarane A.J, Moise S, Smith D. Caesarean section using total intravenous anesthesia in a patient with Ebstein's anomaly complicated by supraventricular tachycardia. *Int J Obstet Anesth* 2007; 16 (2); 155-9.

CASE REPORT



T.Krishnaveni, Age 45 Years

Figure 1: Chest X Ray showing Cardiomegaly

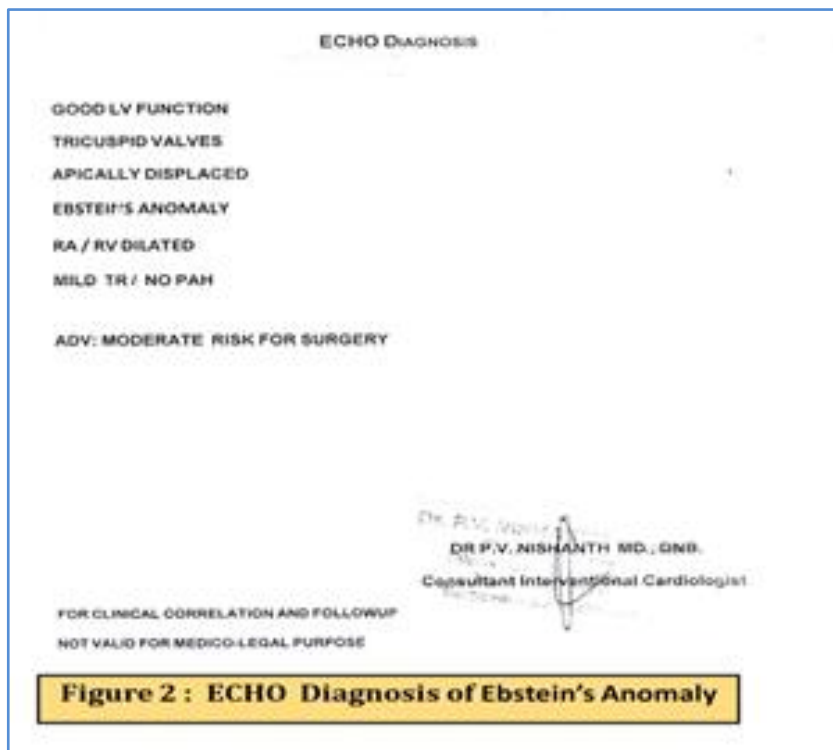


Figure 2 : ECHO Diagnosis of Ebstein's Anomaly

CASE REPORT

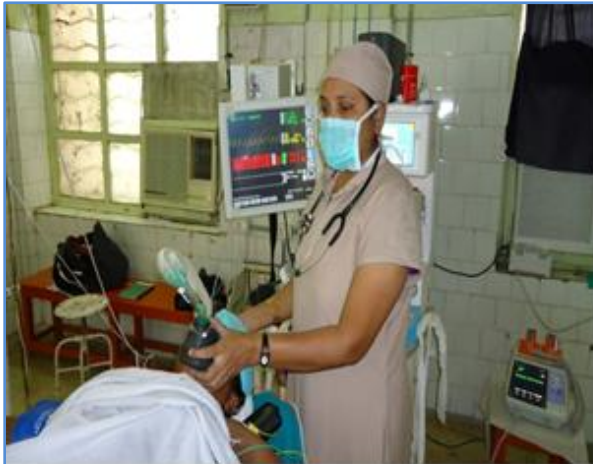

Figure 3: Before Surgery

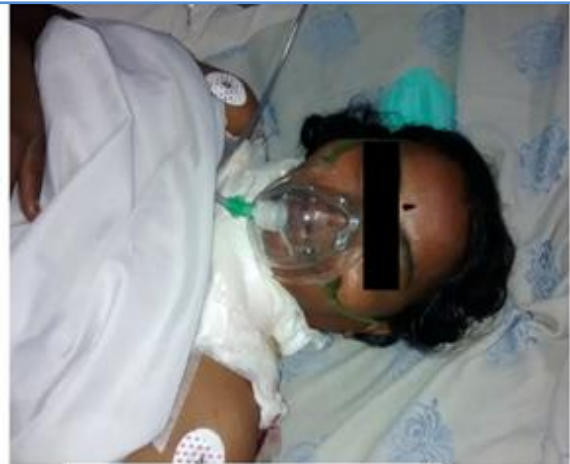

Figure 4: After Surgery

AUTHORS:

1. Snehalatha Bhashyam
2. P. Krishna Prasad
3. B. Sowbhagya Lakshmi
4. K. V.P. Bramhaji Rao

PARTICULARS OF CONTRIBUTORS:

1. Assistant Professor, Department of Anaesthesiology and Critical Care, Ranagaraya Medical College, Government General Hospital, Kakinada.
2. Associate Professor, Department of Anaesthesiology and Critical Care, Ranagaraya Medical College, Government General Hospital, Kakinada.
3. Professor & HOD, Department of Anaesthesiology and Critical Care, Ranagaraya Medical College, Government General Hospital, Kakinada.

4. Post Graduate, Department of Anaesthesiology and Critical Care, Ranagaraya Medical College, Government General Hospital, Kakinada.

NAME ADDRESS EMAIL ID OF THE CORRESPONDING AUTHOR:

Dr. Snehalatha Bhahsyam,
H. No. 8-11-18/1,
Opp. Indian Red Cross Society,
Red Cross Street,
Gandhinagar, Kakinada-533004.
Email: snehabhashyam@gmail.com

Date of Submission: 19/09/2014.
Date of Peer Review: 20/09/2014.
Date of Acceptance: 29/09/2014.
Date of Publishing: 06/10/2014.